

# Radiculopathic Pain: Diagnosis and Treatment of Segmental Irritation or Sensitization

C. Chan Gunn

## *INTRODUCTION*

Medical diagnosis traditionally presumes that pain is a signal of tissue injury conveyed to the central nervous system via a healthy nervous system; the definition of pain, as given by the International Association for the Study of Pain, underscores this—"an unpleasant sensory and emotional experience associated with actual or potential tissue damage, or described by the patient in terms of such damage." However, though pain may be linked causally to tissue injury, it need not be so. Injury does not always generate pain, nor does pain always signal injury. Pain perception can arise from non-noxious input, and spurious pain can arise from within the body when there is some functional disturbance in the nervous system, i.e., neurogenic pain. This manuscript reviews a large category of pain that can arise without injury or inflammation when there is abnormal function in the peripheral nervous system, i.e., peripheral neuropathy (1,2).

## *NEUROPATHIC AND RADICULOPATHIC PAIN*

Not all physicians are familiar with the condition of peripheral neuropathy (3). It may be defined as a condition that causes disordered function in

---

C. Chan Gunn, MD, is President of ISTOP, The Institute for the Study and Treatment of Pain, Vancouver, BC; Medical Director, Gunn Pain Clinic, Vancouver, BC; and Clinical Professor, Multidisciplinary Pain Center, University of Washington, Seattle, WA, USA.

Address correspondence to: C. Chan Gunn, Gunn Pain Clinic, 828 West Broadway, Vancouver, BC, Canada V5Z 1J8.

Submitted: December 11, 1996.

Revision accepted: January 28, 1997.

Journal of Musculoskeletal Pain, Vol. 5(4) 1997  
© 1997 by The Haworth Press, Inc. All rights reserved.

119

the peripheral nerve. Although sometimes associated with structural changes in the nerve, a neuropathic nerve can, deceptively, appear normal: it still conducts nerve impulses, synthesizes and releases transmitted substances and evokes action potentials and muscle contraction.

The function and integrity of innervated structures are contingent on the flow of nerve impulses in the intact nerve to provide a regulatory or "trophic" effect. When this flow [probably a combination of axoplasmic flow and electrical input] is blocked, innervated structures are deprived of the trophic factor which is necessary for the control and maintenance of cellular function. "A-trophic" structures become highly irritable and develop abnormal sensitivity or supersensitivity according to Cannon and Rosenblueth's Law of Denervation (4,5):

When a unit is destroyed in a series of efferent neurons, an increased irritability to chemical agents develops in the isolated structure or structures, the effect being maximal in the part directly denervated.

All denervated structures develop supersensitivity [including skeletal muscle, smooth muscle, spinal neurons, sympathetic ganglia, adrenal glands, sweat glands, and brain cells]. Cannon and Rosenblueth's original work was based on total denervation or decentralization for supersensitivity to develop, accordingly, they named the phenomenon denervation supersensitivity. But it is now known that physical interruption and total denervation are not necessary: any circumstance that impedes the flow of motor impulses for a period of time can rob the effector organ of its excitatory input and cause disuse supersensitivity in that organ and in associated spinal reflexes (6).

The importance of disuse supersensitivity cannot be overemphasized. When a nerve malfunctions, the structures it supplies become supersensitive and will behave abnormally. These structures over-react to many forms of input, not only chemical, but physical inputs as well, including stretch and pressure. Supersensitive muscle cells can generate spontaneous electrical impulses that trigger false pain signals or provoke involuntary muscle activity (7). Supersensitive nerve fibers become receptive to chemical transmitters at every point along their length instead of at their terminals only. Sprouting may occur, and denervated nerves are prone to accept contacts from other types of nerves including autonomic and sensory nerve fibers. Short circuits are possible between sensory and autonomic [vasomotor] nerves and may contribute to "reflex sympathetic dystrophy" or the "complex regional pain syndrome."

Disuse supersensitivity is basic and universal, yet not at all well known or credited. The important role of supersensitive structures following neu-

ropathy or denervation has been, until recently, neglected. Many diverse pain syndromes of apparently unknown causation may be attributed to the development of hypersensitive receptor organs and supersensitivity in pain sensory pathways. "Pain following neuropathy" or "neuropathic" pain is now generally used to refer to this large category of pain (1,2), but, in our experience, physical evidence of neuropathy is almost always found in the distribution of both dorsal and ventral rami of segmental nerves, denoting radiculopathy [which is peripheral neuropathy occurring at the nerve root], therefore, "radiculopathic" pain is a more accurate descriptive term.

### ***MYOFASCIAL PAIN—A RADICULOPATHY MODEL***

Chronic pain can occur if there is:

- Ongoing nociception or inflammation—however, persistent nociception is not a common cause of chronic pain, and inflammation, which is easily recognized [redness, increased local temperature, swelling and inflammation] is usually self-limiting, unless there is abnormal immunologic response as in rheumatoid arthritis.
- Psychologic factors such as a somatization disorder, depression, or operant learning processes.
- Abnormal function in the nervous system—"neurogenic" pain can arise from the central nervous system or peripheral nervous system. "Neuropathic" pain refers to pain that can arise when there is altered or abnormal function in the peripheral nervous system. "Myofascial" pain describes neuropathic pain that presents predominately in the musculoskeletal system.

Myofascial pain syndromes often seem puzzling as they arise and persist in the absence of any detectable injury or inflammation—a response occurs and is sustained without a discernible stimulus. Myofascial pain syndromes are mundane and can affect muscles and their connective tissue attachments in all parts of the body, consequently, they are customarily labelled according to the location of the painful part: e.g., "lateral epicondylitis," "Achilles tendonitis" or "frozen shoulder," etc. [see Table 1]. Although they are generally regarded as unrelated conditions, myofascial pain syndromes are invariably accompanied by sensory, motor and autonomic findings that denote their common origin in neuropathy.

The Multidisciplinary Pain Center at the University of Washington uses and teaches a system of dry needling that is based on a radiculopathy model

TABLE 1. Common Myofascial Pain Syndromes Caused by the Shortened Muscle Syndrome

Muscles shorten on neuropathy and can compress muscle nociceptors to generate primary pain in muscle. Shortened muscles can also cause secondary pain by mechanically overloading tendons and joints they activate; this increases wear and tear and eventually leads to degenerative changes in these structures. Myofascial pain syndromes are, therefore, of great diversity.

When paraspinal muscles shorten, they press upon nerve roots and can perpetuate radiculopathic pain [see Figure 2]. It is important to note that radiculopathy also involves the autonomic nervous system. Some pain syndromes that may be the result of muscle shortening are listed below.

SYNDROME	SHORTENED MUSCLES
Achilles tendonitis	gastrocnemii, soleus
Bicipital tendonitis	biceps brachii
Bursitis:	
—pre-patellar	quadriceps femoris
Capsulitis:	
—shoulder, "Frozen Shoulder"	all muscles acting on the shoulder, including trapezius, levator scapulae, rhomboidei, pectoralis major, supra- & infraspinati, teres major & minor, subscapularis, deltoid
Chondromalacia patellae	quadriceps femoris
De Quervain's tenosynovitis	abductor pollicis longus, extensor pollicis brevis
Diffuse myofascial pain syndrome	generally, muscles supplied by cervical and lumbar nerve roots
Facet Syndrome	muscles acting across the joint, e.g., rotatores, multifidi, semispinalis
Hallux valgus	extensor hallucis longus & brevis
Headaches:	
—frontal	upper trapezius, sternomastoid, occipitofrontalis
—temporal	temporalis, upper trapezius
—vertex	splenius capitis, cervicis
—occipital	suboccipital muscles

SYNDROME	SHORTENED MUSCLES
Idiopathic edema	lymphatic smooth muscles
Infrapatellar tendonitis	quadriceps femoris
Intervertebral disc [early stages]	muscles acting across the disc space, e.g., rotatores, multifidi, semispinalis
Juvenile kyphosis & scoliosis	unbalanced paraspinal muscles
"Low back sprain"	paraspinal muscles: e.g., iliocostalis lumborum & thoracis; also see "intervertebral disc"
Plantar fasciitis	flexor digitorum brevis, lumbricals
Piriformis syndrome	piriformis muscle
Rotator cuff syndrome	supra- & infraspinati, teres minor, subscapularis
"Shin splints"	tibialis anterior
Temporomandibular joint [TMJ]	masseter, temporalis, pterygoids
Tennis elbow	brachioradialis, extensor carpi ulnaris, extensor carpi radialis brevis & longus, extensor digitorum, anconeus

Reproduced with permission from C.C. Gunn, *The Gunn Approach to the Treatment of Chronic Pain—Intramuscular Stimulation [IMS] for Myofascial Pain Syndromes of Radiculopathic Origin*. Published by Churchill Livingstone, 1996.

for chronic pain. Examination, diagnosis, treatment, as well as progress of therapy are all determined according to physical signs of radiculopathy (8). The radiculopathy model, its system of examination and rationale for selection of points for treatment is referred to as Intramuscular Stimulation [IMS], to distinguish it from other methods of needling or injection. The effective application of IMS requires a sound background in anatomy and neurophysiology (9). Intramuscular Stimulation has now been adopted for the treatment of myofascial pain at many treatment centers throughout the world. The radiculopathy model was developed from the writer's clinical observations and research carried out over a period of more than twenty years [first, at the Workers' Compensation Board of British Columbia, and subsequently, at the writer's pain clinic]. Some observations that led to the radiculopathy model are:



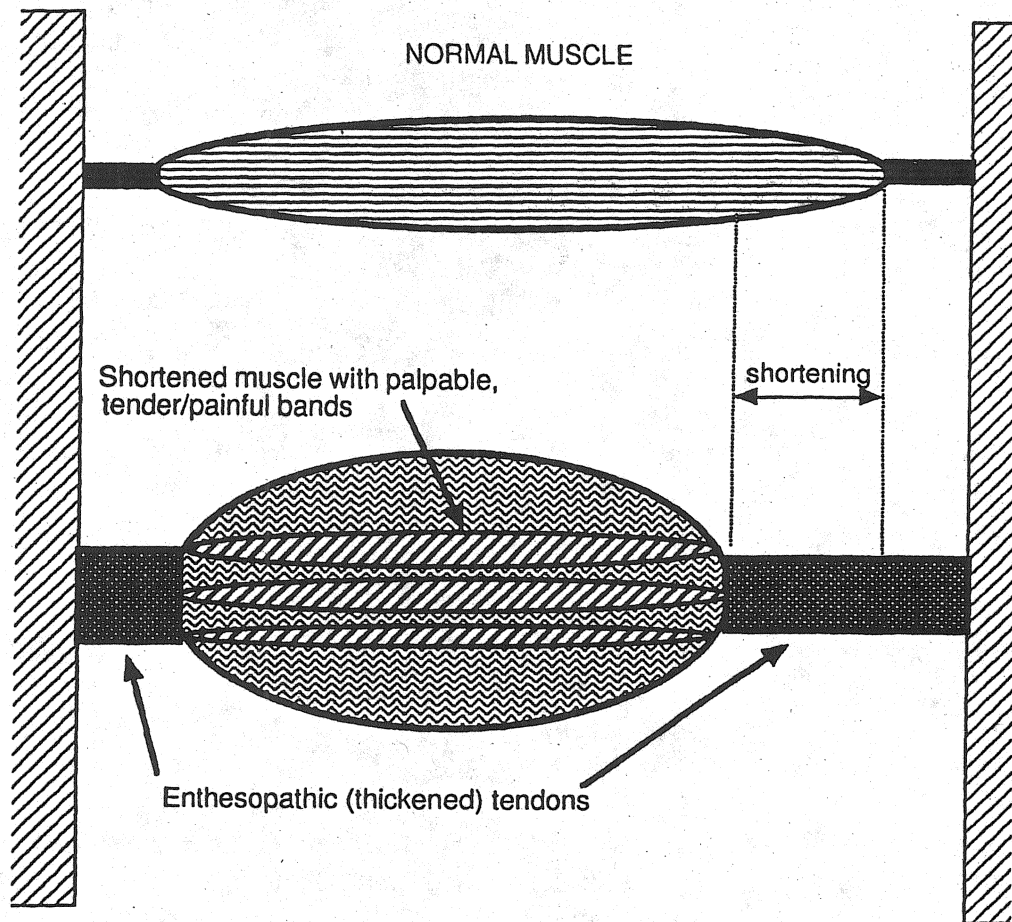
- Points found to be effective for treatment are nearly always situated close to known neuroanatomic entities, such as, muscle motor points or musculotendinous junctions [these points often coincide with acupuncture points (10)].
- Effective treatment points generally belong to the same segmental level[s] as presenting symptoms or the injury (9).
- These points generally coincide with palpable muscle bands that are tender to digital pressure and are generally referred to as trigger points (8).
- Tender points are distributed in a segmental or myotomal fashion, in muscles supplied by both anterior and posterior primary rami—indicative of radiculopathy. Neuropathic pain is especially common in “prespondylosis,” the early stage of spondylosis when neuropathy is already present, but unsuspected. Much less commonly, the distribution is that of a mononeuropathy.
- Muscles with tender points are generally shortened from contracture (9) [See Figure 1].
- Virtually every condition that responds to needling demonstrates signs of peripheral neuropathy (8); these signs are not well known, and are therefore frequently missed.
- Symptoms and signs typically disappear when the tender and shortened muscle bands are needled and contractures released.

Intramuscular Stimulation practitioners purposely seek out tender and tight muscle bands in affected segments for needling. Following needling, physical signs of peripheral neuropathy, such as muscle contracture [“spasm”], vasoconstriction and tenderness can disappear within seconds or minutes. [It is extremely satisfying to see these signs disappear before one’s eyes.] Other signs, like trophedema, diminish more gradually, maybe taking days or even weeks to disappear; ultimately, all signs vanish following successful treatment.

### ***RADICULOPATHY— ITS FREQUENT RELATIONSHIP TO SPONDYLOSIS***

It is not unusual for the flow of nerve impulses to be obstructed. Peripheral neuropathy, often accompanied by partial denervation, is not exceptional in adults. Of the innumerable causes of nerve damage, such as trauma, metabolic, degenerative, toxic, and other conditions, chronic attrition from spondylosis [the structural disintegration and morphologic alterations that occur in the intervertebral disc, with pathoanatomic changes in

FIGURE 1. Neuropathy can cause muscle contracture with concurrent muscle shortening.



Reproduced with permission from C.C. Gunn, *The Gunn Approach to the Treatment of Chronic Pain: Intramuscular Stimulation [IMS] for Myofascial Pain of Radiculopathic Origin*, 2nd Edition. Published by Churchill Livingstone, September 1996.

surrounding structures] is by far the most common. The spinal nerve root, because of its vulnerable position, is notably prone to injury from pressure, stretch, angulation, and friction. [Other causes of radiculopathy, such as arachnoiditis, neuroma, and intraspinal tumors are much less common]. Spondylosis increases with age, therefore, spondylitic pain is more common in middle-aged individuals who have accumulated an "injury pool"—an accumulation of repeated major and minor injuries to a segment leading to unresolved clinical residuals which may, or may not, produce pain (11).

Ironically, neuropathy itself contributes to degenerative conditions [including spondylosis!]. Neuropathy degrades the quality of collagen, caus-

ing it to have fewer cross-links; it is therefore frailer than normal collagen (12). The amount of collagen in soft and skeletal tissues is also reduced. Because collagen lends strength to ligament, tendon, cartilage, and bone, neuropathy can expedite degeneration in weight-bearing and activity-stressed parts of the body—which include the spine and joints.

Ordinarily, spondylosis follows a gradual, relapsing, and remitting course that is silent, unless and until, symptoms are precipitated by an incident often so minor that it passes unnoticed by the patient. All gradations of spondylosis can exist, but early or incipient spondylitic changes, even when unsuspected, can nevertheless irritate and upset function in the segmental nerve.

Our emphasis on radiculopathy is not without reason: with an acute injury to a healthy nerve, there is no prolonged discharge of pain signals, whereas, the same injury to a neuropathic nerve can cause a sustained discharge. In other words, for pain to become a persistent symptom, the affected fibers must be previously irritated or defective. That is why some people develop severe pain after an apparently minor injury, and why that pain can continue beyond a “reasonable” period.

## ***CHALLENGES IN DIAGNOSIS AND TREATMENT***

### ***Clinical Diagnosis***

Diagnosing pain and dysfunction caused by radiculopathy depends almost entirely on the examiner’s clinical experience and acumen. The history gives little assistance. Pain often arises spontaneously with no history of trauma, or else the degree of reported pain far exceeds that consistent with the injury. Some features that indicate neuropathic pain are (13):

- Pain when there is no ongoing tissue-damaging process;
- Delay in onset after precipitating injury. [It generally takes five days for supersensitivity to develop.]
- Dyscesthesia—unpleasant “burning or searing” sensations, or “deep, aching” pain which is more common than dysesthetic pain in musculoskeletal pain syndromes;
- Pain felt in a region of sensory deficit;
- Neuralgic pain; paroxysmal brief “shooting or stabbing” pain;
- A mild stimulus can cause extreme pain.
- Pronounced summation and after-reaction with repetitive stimuli.



Other features are:

- Loss of joint range or pain caused by the mechanical effects of muscle shortening;
- Abnormal bowel function [e.g., "irritable bowel syndrome"];
- Increased vasoconstriction or hyperhidrosis;
- "Causalgic pain"; "reflex sympathetic dystrophy" or "complex regional pain syndrome."

### *Laboratory and Radiologic Findings*

These are generally not helpful. Thermography reveals decreased skin temperature in affected dermatomes and this can be an indication of neuropathy but does not necessarily signify pain or identify individual painful muscles. Radiculopathies are difficult to document with routine nerve conduction studies which measure only the few fastest-conducting and largest fibers and take no account of the majority of smaller fibers. In focal neuropathy, nerve conduction velocities remain within the wide range of normal values, but F-wave latency may be prolonged. Electromyography is not specific either.

Signs of neuropathy are subtle and differ from those of outright denervation [such as loss of sensation and reflexes]. It is important to remember that in radiculopathy, signs are generally present in the territories of both posterior and anterior primary divisions of the affected nerve root, consequently, symptoms are projected onto the dermatomal, myotomal, and sclerotomal target structures supplied by the affected neural structure. The effects of radiculopathy vary according to the type [sensory, motor, autonomic, or mixed] and distribution of nerve fibers involved.

A careful inspection for signs of motor, sensory and autonomic [vasomotor, sudomotor and pilomotor] dysfunction in the skin and affected muscles is necessary. Vasoconstriction differentiates neuropathic pain from inflammatory pain: in neuropathic pain, affected parts are perceptibly colder. There may be increased sudomotor activity and the pilomotor reflex is often hyperactive and visible in affected dermatomes as "goosebumps" (8). There can be interaction between pain and autonomic phenomena. A stimulus such as chilling, which excites the pilomotor response, can precipitate pain; vice versa, pressure upon a tender motor point can provoke the pilomotor and sudomotor reflexes.

Increased tone in lymphatic vessel smooth muscle, and increased permeability in blood vessels (8) can lead to local subcutaneous tissue edema ["neurogenic" edema or "trophedema"]. This can be confirmed by the *peau d'orange* effect [orange peel/skin] or by the "Matchstick" test [tro-

phedema is non-pitting to digital pressure, but when a blunt instrument such as the end of a matchstick is used, the indentation produced is clear-cut and persists for many minutes (8)]. This simple test for neuropathy is more sensitive than electromyography. Trophic changes such as dermatomal hair loss may also accompany neuropathy.

### ***Knowledge of the Segmental Nerve Supply to Muscles Is Clue to Diagnosis and Treatment***

Changes are primarily in muscle: even when symptoms appear to be in joints or tendons, signs in the muscles are the most consistent and relevant—increased muscle tone; tenderness over motor points; taut and tender, palpable contracture bands and resultant restricted joint range. Each constituent muscle must be palpated and its condition noted. Palpation requires detailed knowledge of anatomy and clinical skill comes only with practice. Moreover, because many paraspinal muscles are compound [e.g., the longissimus] and extend throughout most of the length of the vertebral column, the entire spine must be examined even when symptoms are localized to one region.

### ***The Needle as a Powerful Diagnostic and Treatment Tool***

The fine, flexible, solid needle is more than a therapeutic tool, it is also a unique and powerful diagnostic instrument. Contracture is invisible to X-rays, computerized tomography [CT] scans, or magnetic resonance imaging [MRI], and contracture in deep muscles is beyond the finger's reach. Deep contracture can only be discovered by probing with a needle. The fine, flexible needle transmits feedback information on the nature and consistency of the tissues that it is penetrating. When it penetrates normal muscle, the needle meets with little hindrance; when it penetrates a contracture, there is firm resistance, and the needle is grasped by the muscle [causing the patient to feel a peculiar, cramping or grabbing sensation described by acupuncturists as the "Deqi response"]. When the needle enters fibrotic tissue, there is a grating sensation [like cutting through a pear]. Sometimes, the resistance of a fibrotic muscle is so intense that its hardness is mistaken for bone, and frequently, increased pressure on the needle may be required to force it in. The examiner, guided by the needle-grasp and the Deqi response, is able to identify a distressed segment quickly, and with greater accuracy than with X-rays, scans, or MRIs. Indeed, radiological findings may be misleading as they cannot distinguish an old, non-active lesion from an ongoing, irritable one.

### ***Release of Muscle Shortening Is Key to Treatment***

Muscle shortening is a fundamental feature of musculoskeletal pain syndromes, and of all the structures that develop supersensitivity, the most widespread and significant is striated muscle. Muscle shortening can physically cause a large variety of pain syndromes by its relentless pull on various structures (14), [see Figures 1 and 2 and Table 1].

When irritation to a nerve is minor, neuropathy is a transient and self-limiting condition; but when contracture-caused shortened muscles are present, their release is necessary to relieve pain and restore joint range and function. When the several most painful shortened bands in a muscle are released, relaxation of the entire muscle usually follows (15).

Although it is no longer held that muscle pain can occur from the compression of normal nociceptors (16), pain can probably be caused by compression of nociceptors that are supersensitive.

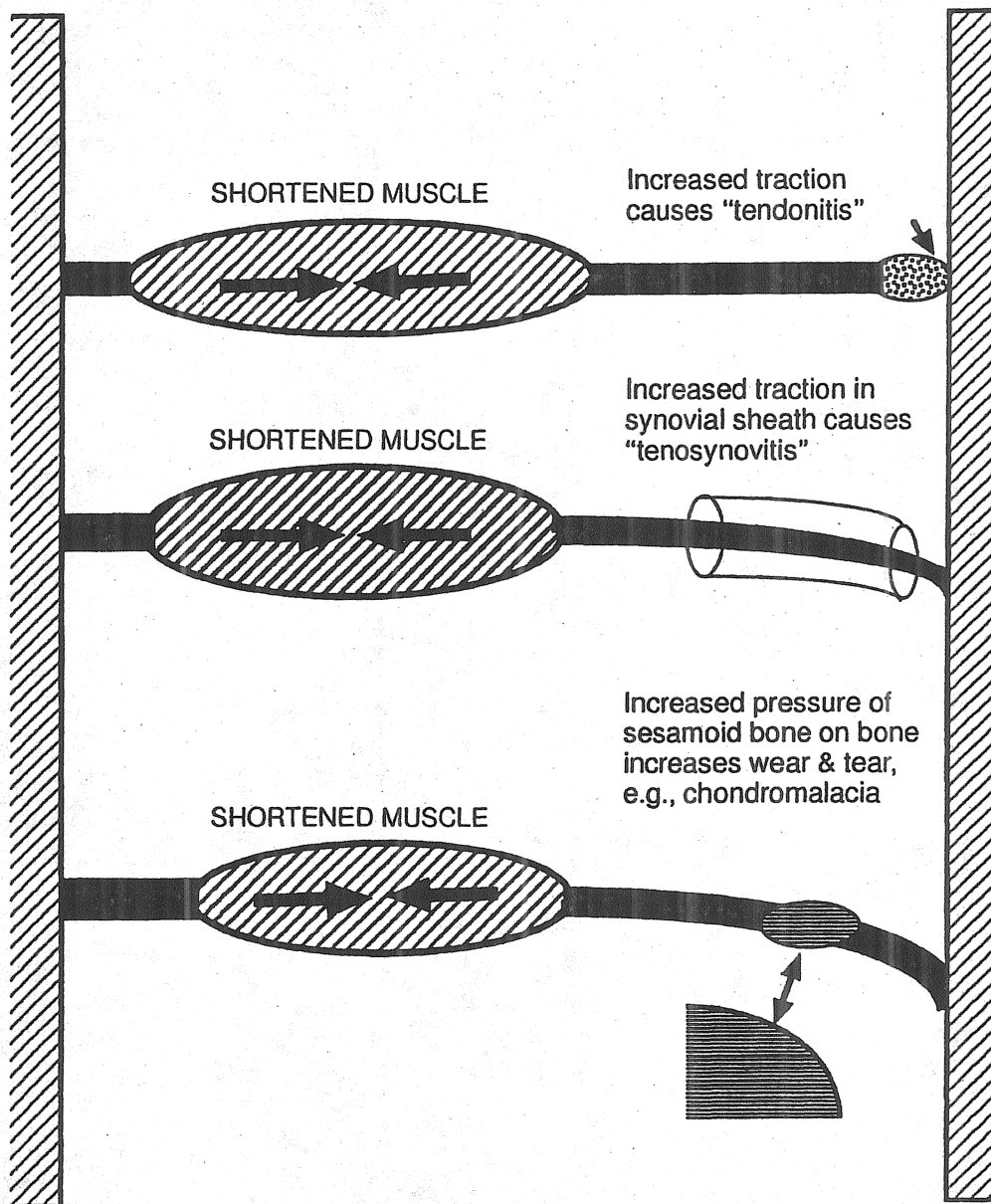
In recurrent or chronic pain, fibrosis eventually becomes a major feature of the contracture; response to dry needle treatment is then much less dramatic and less effective. The extent of fibrosis present is not necessarily correlated with chronologic age: scarring can occur after injury or surgery, and many older individuals have sustained less wear and tear than younger ones who have subjected their musculature to repeated physical stress. The treatment of extensive fibrotic contractures necessitates more frequent and extensive needling because release of the contracture is usually limited to the individual muscle bands needled. To relieve pain in such a muscle, it is necessary to needle all tender bands. It is uncommon to encounter a muscle that is totally fibrotic and cannot be released by accurate, vigorous needling.

For long-lasting pain relief and restoration of function, it is essential to release shortened paraspinal muscles that may be compressing a disc, and disperse fibrotic tissue that is entrapping a nerve root [see Figure 3]. Even in such situations, surgical intervention is rarely necessary as the needle can reach and release deeply located shortened muscles.

### ***DISCUSSION AND IMPLICATIONS***

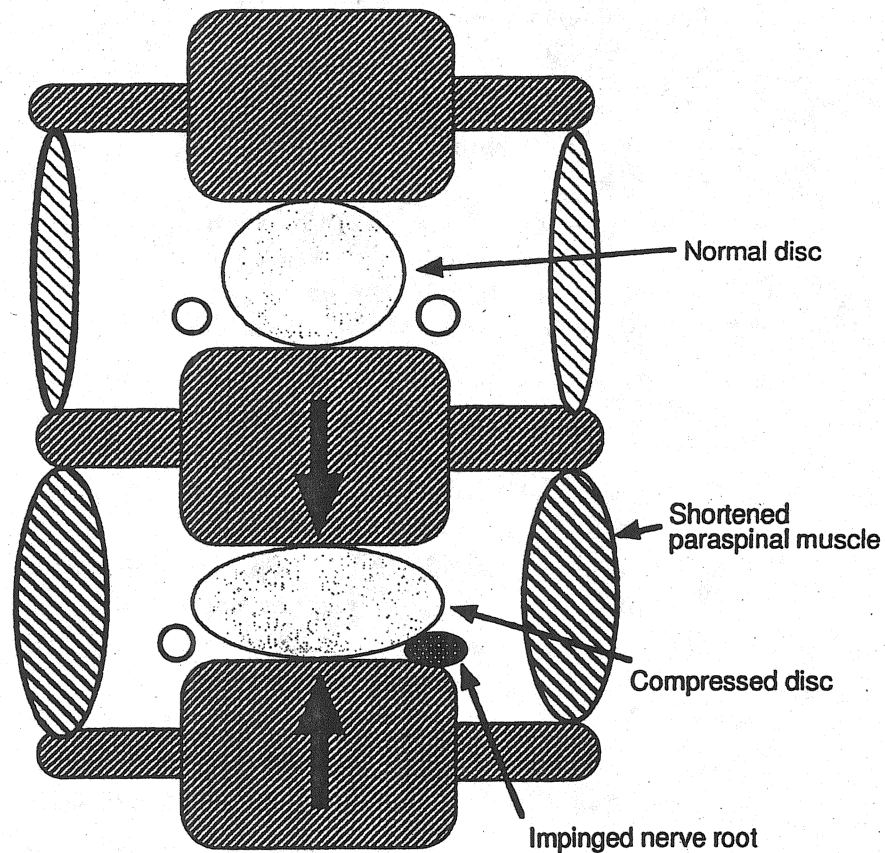
The mechanism of neuropathic pain is different from nociception and inflammation, its diagnosis and treatment consequently require different approaches. Diagnosis is mainly clinical because laboratory and radiological tests are unhelpful in early neuropathy. Diagnosis is confirmed by signs of neuropathy that are different from the well-known ones of outright denervation, such as absent reflexes and loss of sensation. These

FIGURE 2. Shortening creates tension in tendons and their attachments and can cause such syndromes as epicondylitis, tendonitis, tenosynovitis, or chondromalacia patellae.



Reproduced with permission from C.C. Gunn, *The Gunn Approach to the Treatment of Chronic Pain: Intramuscular Stimulation [IMS] for Myofascial Pain of Radiculopathic Origin*, 2nd Edition. Published by Churchill Livingstone, September 1996.

FIGURE 3. Shortened paraspinal muscles across an intervertebral disc space can compress the disc and impinge on the nerve root.



Reproduced with permission from C.C. Gunn, *The Gunn Approach to the Treatment of Chronic Pain: Intramuscular Stimulation [IMS] for Myofascial Pain of Radiculopathic Origin*, 2nd Edition. Published by Churchill Livingstone, September 1996.

subtle signs can be found if the clinician knows to where to look, and what to look for.

Treatment of neuropathic pain is also different. Supersensitivity requires desensitization by the alleviation of neuropathy. Nerve entrapments are usually obvious and rarely may require surgical release; however, neural irritation and neuropathy often occur without entrapment.

Lomo has shown that supersensitivity and all the other features of denervation in muscle can be reversed by stimulating the muscle with electricity. Continuous electrical stimulation is able to counteract "disuse" supersensitivity and substitute for the trophic factor that is diminished or absent in neuropathy (17).



All physical and counter-irritational therapies, including acupuncture, achieve their effect by reflex-stimulation and they are effective only if the nerve to the painful part is still intact. Their application excites receptors [in skin and muscle] and stimulates their target reflexively. For example, massage and focal pressure activate tactile and pressure receptors; exercise, traction and manipulation stimulate muscle spindles and Golgi organs; heat [including ultrasound] and cold act on thermal receptors. These stimuli are sensed by their specific receptors, transduced into electrical signals and relayed to the spinal cord; thus, all forms of physical therapy may be likened to electrical stimulation. As with the patellar reflex, stimulation reaches the affected part via a reflex. It is the reflex response in efferent fibers to the affected structure that stimulates the therapeutic target. Therapy is effective only if the nerve to the painful part is still functioning, and its effect is blocked by a local anesthetic.

Unfortunately, all external forms of physical therapy have a critical drawback. They are passive, and when application is halted, stimulation ceases. Ideally, stimulation should use the body's own bio-energy, which can be recruited in the form of the "current of injury." First described by Galvani in 1797, this current is generated when tissue is injured, for example, following injection or dry needling techniques including acupuncture (18). When the needle pierces muscle, it disrupts the cell membrane of individual muscle fibers, mechanically discharging a brief outburst of injury potentials referred to as "insertional activity." Injury potentials delivered on needle insertion are able to relax a shortened muscle instantly or within minutes. Needling also induces a sympatholytic effect that spreads throughout the body segment, releasing vasoconstriction. Pain in muscles, tendons and joints caused by excessive muscle tension is eased when the shortened muscles are relaxed. Subjective improvement [which can sometimes occur within minutes] can be confirmed objectively; for example, as an increase in joint range, or minor degrees of joint effusion may resolve and any decrease in muscle tenderness can be measured by the use of a pressure algometer (19). Endogenous opiates, now used to explain needling techniques, such as acupuncture, cannot account for all the observed effects.

Unlike external forms of stimulation, stimulation from a needle lasts for several days until the miniature wounds heal. Needling has another unique benefit unavailable to other forms of local therapy: It delivers to the injured area the platelet-derived growth factor which induces deoxyribonucleic acid synthesis and stimulates collagen formation (20). Body cells are normally exposed to a filtrate of plasmas [interstitial fluid] and would

only see the platelet factor in the presence of injury, hemorrhage and blood coagulation.

### CONCLUSION

The radiculopathy model has been proposed as an hypothesis to explain chronic musculoskeletal pain problems of obscure origin. The model enables many apparently dissimilar musculoskeletal pain syndromes to be grouped under one etiologic classification [radiculopathy]. The efficacy of IMS therapy for chronic low back pain has been demonstrated by a randomized clinical trial involving a large group of patients in the British Columbia Workers' Compensation Board. At their seven-month follow-up, the treated group was clearly and significantly better than the control group (15).

### REFERENCES

1. Gunn CC: "Prespondylosis" and some pain syndromes following denervation supersensitivity. *Spine* 5 (2): 185-192, 1978.
2. Gunn CC: Neuropathic pain: a new theory for chronic pain of intrinsic origin. *Annals of the Royal College of Physicians and Surgeons of Canada* 22 (5): 327-330, 1989.
3. Thomas PK: Symptomatology and Differential Diagnosis of Peripheral Neuropathy: Clinical & Differential Diagnosis. *Peripheral Neuropathy*. Edited by PJ Dyck, PK Thomas, EH Lambert, R Bunge. WB Saunders, Philadelphia, 1984, pp. 1169-1190.
4. Cannon WB, Rosenblueth A: The Supersensitivity of Denervated Structures, A Law of Denervation. The MacMillan Company, New York, 1949.
5. Thesleff S, Sellin LC: Denervation supersensitivity. *Trends in NeuroSciences* August:122-126, 1980.
6. Sharpless SK: Supersensitivity-like phenomena in the central nervous system. *Federation Proceedings* 34(10):1990-1997, 1975.
7. Culp WJ, Ochoa J: Abnormal Nerves and Muscles as Impulse Generators. Oxford University Press, New York, 1982.
8. Gunn CC, Milbrandt WE: Early and subtle signs in low back sprain. *Spine* 3(3):267-281, 1978.
9. Gunn CC: The Gunn Approach to the Treatment of Chronic Pain—Intramuscular Stimulation for Myofascial Pain of Radiculopathic Origin. Churchill Livingstone, London, 1996.
10. Gunn CC, Ditchburn FG, King MH, Renwick GJ: Acupuncture loci: A proposal for their classification according to their relationship to known neural structures. *American Journal of Chinese Medicine* 4 (2):183-195, 1976.

11. Sola AE: Treatment of myofascial pain syndromes. *Advances in Pain Research and Therapy*. Edited by C Benedetti, CR Chapman, and G Morrica. Raven Press, New York, 1984, Vol. 7, pp. 467-485.
12. Klein L, Dawson MH, Heiple KG: Turnover of collagen in the adult rat after denervation. *J Bone Jt Surgery* 59A:1065-1067, 1977.
13. Fields HL: *Pain*. McGraw-Hill, New York, 1987, pp. 133-169.
14. Gunn CC: The mechanical manifestations of neuropathic pain. *Annals of Sports Medicine* 5(3):138-141, 1990.
15. Gunn CC, Milbrandt WE: Dry needling of muscle motor points for chronic low back pain. A randomized clinical trial with long-term follow-up. *Spine* 5(3):279-291, 1980.
16. Mense S: Nociception from skeletal muscle in relation to clinical muscle pain. *Pain* 54: 241-289, 1993.
17. Lomo T: The role of activity in the control of membrane and contractile properties of skeletal muscle. *Motor Innervation of Muscle*. Edited by S Thesleff. Academic Press, New York, 1976, pp. 289-316.
18. Jaffe LF: Extracellular current measurements with a vibrating probe. *TINS* December: 517-521, 1985.
19. Fisher AA: Pressure algometry (dolorimetry) in the differential diagnosis of muscle pain. In Rachlin ES, *Myofascial Pain and Fibromyalgia, Trigger Point Management*. St. Louis: Mosby, 1994, pp. 1231-1241.
20. Ross R, Vogel A: The platelet-derived growth factor. *Cell* 14:203-210, 1978.